

HISTOLOGIC, NEUROLOGIC, AND IMMUNOLOGIC EFFECTS OF METHYLMERCURY IN CAPTIVE GREAT EGRETS

Marilyn G. Spalding,^{1,9} Peter C. Frederick,² Heather C. McGill,^{1,8} Shannon N. Bouton,² Lauren J. Richey,¹ Isabella M. Schumacher,^{3,7} Carina G. M. Blackmore,^{4,8} and Jay Harrison⁵

¹ Department of Pathobiology, College of Veterinary Medicine, Box 110880, University of Florida, Gainesville, Florida 32611, USA

² Wildlife Conservation and Ecology, University of Florida, Gainesville, Florida 32611, USA

³ Biotechnologies for the Ecological Evolutionary and Conservation Sciences, University of Florida, Gainesville, Florida 32610, USA

⁴ Department of Biological Sciences, University of Notre Dame, Notre Dame, Indiana 56556, USA

⁵ Department of Statistics, University of Florida, Gainesville, Florida 32611, USA

⁶ Current address: 8101 W. Flamingo #2006, Las Vegas, Nevada 89117, USA

⁷ Current address: 8525 Richland Colony Rd., Knoxville, Tennessee 37923, USA

⁸ Current address: Florida Department of Health, Box 210, Jacksonville, Florida 32231, USA

⁹ Corresponding author (e-mail: rosie@nersp.nerdc.ufl.edu)

ABSTRACT: Captive great egret (*Ardea albus*) nestlings were maintained as controls or were dosed with methylmercury chloride at low (0.5), and high doses (5 mg/kg, wet weight) in fish. Low dosed birds were given methylmercury at concentrations comparable to current exposure of wild birds in the Everglades (Florida, USA). When compared with controls, low dosed birds had lower packed cell volumes, dingy feathers, increased lymphocytic cuffing in a skin test, increased bone marrow cellularity, decreased bursal wall thickness, decreased thymic lobule size, fewer lymphoid aggregates in lung, increased perivascular edema in lung, and decreased phagocytized carbon in lung. High dosed birds became severely ataxic and had severe hematologic, neurologic, and histologic changes. The most severe lesions were in immune and nervous system tissues. By comparing responses in captive and wild birds, we found that sublethal effects of mercury were detected at lower levels in captive than in wild birds, probably due to the reduced sources of variation characteristic of the highly controlled laboratory study. Conversely, thresholds for more severe changes (death, disease) occurred at lower concentrations in wild birds than in captive birds, probably because wild birds were exposed to multiple stressors. Thus caution should be used in applying lowest observed effect levels between captive and wild studies.

Key words: *Ardea albus*, captive, contaminants, great egret, immunology, lowest observed adverse effect level, methylmercury, neurology, pathology.

INTRODUCTION

Methylmercury has been well documented as a bioaccumulated contaminant in aquatic ecosystems (Faber and Hickey, 1973; Fimreite, 1974; Stendell et al., 1976; Thomann et al., 1992; Facemire et al., 1995; Meyer et al., 1995; Cleckner et al., 1998; Wolfe and Norman, 1998). Negative effects on the neurological (Chang, 1977; Burbacher et al., 1990; Nagashima, 1997) and immune systems (Ilback, 1991; Ilback et al., 1996) and other tissues (Snelgrove-Hobson et al., 1988) are well documented in humans and captive mammals. Effects of methylmercury exposure have been reported in captive birds (Borg et al., 1970; Fimreite and Karstad, 1971; Soares et al., 1973; Pass et al., 1975; Hughes et al., 1976; Heinz and Hoffman, 1998; Hoffman

and Heinz, 1998), including trans-generational effects (Heinz, 1975, 1976, 1979). These studies have focused on non-piscivorous species, whereas the top predators in aquatic systems are often piscivorous mammals and birds. Although the presence of mercury in the tissues of wild fish-eaters is commonly reported, the health and behavioral effects have only been sporadically documented (Barr, 1986; Spalding et al., 1994; Facemire et al., 1995; Meyer et al., 1998; Scheuhammer et al., 1998; Nocera and Taylor, 1998).

In the Everglades (Florida, USA) where mercury concentrations are high, wading birds appear to be among the species at greatest risk (Jurczyk, 1993; Sundlof et al., 1994). A field dosing experiment to study the effects of methylmercury in nestling

great egret (*Ardea albus*) chicks discovered few to no adverse health effects (Sepulveda et al., 1999b).

We raised captive great egret nestlings from hatching to 14-wk-old, well after the time that they would normally be independent in the wild (about 9- to 19-wk-old, Sepulveda et al., 1999b), as controls and on diets containing 0.5, and 5 mg/kg wet weight of methylmercury. We then compared growth, appetite, health, immune function, survival, behavior, and hunting ability in relation to mercury dose. The effects on growth, appetite, tissue mercury concentrations (Spalding et al., 2000), behavior (Bouton et al., 1999), and tissue and plasma biochemistry (D. J. Hoffman et al., unpubl. data) are, or will be, published elsewhere.

MATERIALS AND METHODS

On 16 March 1996 we collected the first-hatched great egret nestlings from 23 different broods in Alley North colony (26°11.25'N, 80°31.05'W) in Water Conservation Area 3 of the central Everglades. This colony is located within an area where high mercury concentrations have been measured in wading birds and fish (Sundlof et al., 1994; Frederick et al., 1999). Some young were collected as pipped eggs, which took several days to hatch, and others were as old as 5 days. The range in ages was 7 days. The birds were transported to the Florida Field Station of the National Wildlife Research Center (United States Department of Agriculture, Gainesville, Florida USA), where they were housed for the rest of the experiment. A more detailed description of the dosing and housing methods is given in Spalding et al. (2000). Briefly, birds were individually housed indoors in plastic boxes and moved outdoors at 5 wk. During the last third of the experiment, we placed one shallowly flooded plastic wading pool in each cage and allowed birds to catch live fish. All birds received a diet of about 90% thawed Atlantic silversides (*Menidia menidia*) and 10% capelin (*Mallotus villosus*). Food was provided on a modified *ad libitum* basis, as explained in Spalding et al. (2000) and dosing was based on daily food offered. In addition to the controls (5 birds), we used a low dose (5) of 0.5 mg/kg in fish because it was similar to what great egret nestlings in the Everglades currently eat (Frederick et al., 1999), and a high dose (6) of 5 mg/kg in order to produce clinical toxicity.

Gelatin capsules with the appropriate dose were made by evaporating acetone from a solution of methylmercury chloride in acetone, and these were given orally daily from 8 days of age to the end of the experiment at day 95. Control capsules were made by adding and evaporating acetone only. The fish that all birds were fed contained a mean of about 0.02 mg/kg mercury on a wet weight basis. Methylmercury chloride consumed varied with amount of food consumed and ranged from a high of 0.135 mg/kg/day during wk 3 to a low of 0.048 mg/kg/day during wk 13 in the low dose group. Due to an error in handling solutions, the high dose group received 0.5 mg/kg of fish until 6 wk. Assignment to mercury dose groups was blind to researchers working on the experiment.

Blood was collected weekly, prior to daily dosing, beginning at 1 wk of age. Blood collection volumes ranged from 0.1 to 0.3% of body weight and varied depending upon the tests run (0.5 ml for wk 1; 1.6 ml for wk 3, 5, and 7; 0.5 ml for wk 4 and 6; 1 ml for wk 8, 10, 12, and 13; 2.6 ml for wk 9 and 11; and 10 ml just prior to euthanasia for all birds). Blood for white cell counts and differentials was collected on wk 3, 5, 7, 9, 11, and 13. White cell counts were determined using a hemocytometer and the Unopette Test 5877 for eosinophils (Becton Dickinson and Company, Franklin Lakes, New Jersey, USA) (Campbell, 1995). Packed cell volume and plasma proteins were determined during the alternate weeks by centrifugation and refractrometry respectively. Plasma (EDTA) for EEE and BSA titers was collected weekly from 8–14 wk, and for plasma enzymes during wk 5, 7, 9, and 14.

Immune responses were tested during the latter half of the experiment (most high dose birds did not complete the humoral test). All birds were vaccinated with 0.3 ml of a killed eastern equine encephalitis virus (EEEV) vaccine (Fort Detrick, Beltsville, Maryland, USA) in the right pectoral muscle on wk 8, 9, and 11, and in the left pectoral muscle with 200 µg bovine serum albumin (BSA, heat-shock treated, FisherBiotech, Fairlawn, New Jersey, USA) in 0.1 ml sterile saline on wk 8 and 10. BSA titers (serial two-fold dilutions starting at 1:10) were measured by an enzyme-linked immunosorbent assay (Lung et al., 1996) using alkaline phosphate labeled goat anti-chicken immunoglobulin G (6100-04, Southern Biotechnology Associates Inc., Birmingham, Alabama, USA). For EEEV antibody testing serum samples were diluted with an equal volume of cell culture medium (Medium, 199 with 10% serum supplement and antibiotics, Sigma, St. Louis, Missouri, USA), heat-inactivated for 30 min in

a 56 C waterbath, and assayed for EEEV antibodies by the constant virus-serum dilution neutralization test (Pantuwatana et al., 1972; Lindsey et al., 1976). Serial two-fold dilutions of the specimens were made in 96-well microtiter plates and tested for neutralization of 100 median tissue culture infectious doses (TCID₅₀)/0.025 ml of EEEV in Vero cells (9,700 cells/well). Virus isolates (strain NJ/60) passed once in mosquito cells, five times in sucking mouse brains and twice in Vero cells) and mouse hyperimmune ascitic fluid (SMA 48612) were obtained from Centers for Disease Control (Fort Collins, Colorado, USA). After a 5-day incubation, the plates were fixed and stained. Antibody titers were recorded as the highest dilution of serum with less than 50% cytopathic effect on the Vero cell monolayer. Sera neutralizing virus at a 1:4 dilution or higher were considered positive for specific antibodies. Phytohemagglutinin (PHA, L 8754, 0.1 ml (1 mg/ml), Sigma, St. Louis, Missouri, USA), in phosphate buffered saline was injected intradermally into the left wing web during wk 11. The response area was measured 24 hr later with calipers and a biopsy collected and preserved in 10% neutral buffered formalin (NBF).

Neurologic examinations were performed on all birds during wk 10, then were repeated on the high dose birds just prior to euthanasia (wk 10 to 12) and on the control and low dose birds during wk 13. Birds were ranked on a scale from 1 to 3 or 1 to 5 for their response to the following tests: alertness, intention movements, standing posture, hock sitting posture, perching posture, wing posture, gait, voice, begging, crest posture, flight to a perch, wing response (to being pulled out, to falling, to twisting the body), leg response (to knuckling toes under, placing, grasping a stick, patellar reflex, superficial pain, deep pain), response to sound, eye response (to following an object, menace, head movement up and turning, light, light in opposite eye, corneal touch), palpebral response, and gag reflex. In addition feather cleanliness was evaluated on wk 7, 9, and 10. The time to return to an upright posture when placed on their backs also was measured on wk 6, 8, 10, 12, and 13.

Birds in the high dose group were killed humanely by lethal injection of sodium pentobarbital when they could no longer stand at wk 10 (1 individual), 11(2), and 12(3), and all remaining birds were killed humanely at the end of the experiment (wk 14). A complete necropsy examination was performed within 2 hr. Tissues were saved frozen and in 10% NBF until analysis. Histologic slides were prepared routinely and stained with hematoxylin and eosin. Brain

and spinal cord sections also were stained with luxol fast blue (LFB, Lillie, 1976). Tissues were examined for lesions without knowledge of the dose group, and each was ranked or measured according to severity. Since there were five males and 11 females in the study one of the observations that was based upon a similar cell type in gonads was ranked by first ranking the testes and ovary separately then combining them by alternately ranking the highest male, the highest two females, the next highest male, etc. Tissues were tested for total mercury concentrations using cold vapor atomic absorption spectroscopy as described by Spalding et al. (2000). Total mercury concentrations are reported and discussed on a wet weight basis unless stated otherwise.

We used repeated measures analysis of variance (ANOVA) with multiple comparisons to test for effects of dose group on various responses by the chicks (SAS Institute, 1988), and included age and sex as covariates, since ages varied by 7 days and great egrets are sexually dimorphic. Measurements were made either weekly or biweekly, and the effect of week was included as a covariate in all models. Significant effects of group \times wk interactions were interpreted as evidence of an effect of methylmercury dose. Probabilities of <0.05 were considered significant. For multiple comparisons probabilities of less than 0.01 were considered significant. We compared differences in neurological observations among groups using a Mann-Whitney *U* test (Siegel, 1956). Stepwise discriminant analysis (SDA) was used to test for differences in histologic changes among dose groups (SAS Institute, 1988). Since we were interested primarily in the low dose effects, the control and low dose groups were compared with a separate discriminant analysis test to provide a better estimate of variation within those two groups.

RESULTS

Hematology

Packed cell volume (PCV) increased gradually with age for all birds (Fig. 1). Dose group had a significant effect on PCV (ANOVA, $P = 0.0002$). PCV was significantly and transiently lower in the low dose group than in controls for wk 5, 7–10 and began prior to initiation of the high dose and continued during wk 7, 9–11 (only two birds remained for wk 12). At 5 wk dosed birds were receiving 0.102 mg methylmercury/kg/day. A transient decrease in PCV was observed on alternate

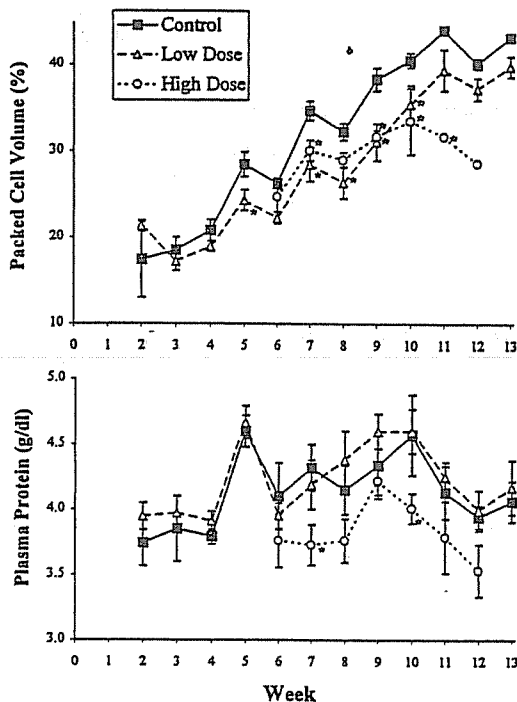


FIGURE 1. Weekly packed cell volume (PCV) and plasma protein determinations from great egret chicks dosed with methylmercury. High dose birds received the low dose until wk 5 and are combined with the low dose group during that period. Symbols with * differ significantly from the control group ($P < 0.01$).

weeks, following the larger blood collections in all groups. A significant increase in polychromatic red blood cells was recorded during wk 7 for the high dose group ($P = 0.0028$)(Table 1).

We found a significant effect of dose group on plasma proteins ($P = 0.030$). Plasma proteins were lower in the high dose birds in wk 7, 10 (Fig. 1). Only two birds remained in the high dose group by wk 12. A peak in all groups during wk 5 may have been due to moving birds to outdoor housing.

We noted several significant differences in the numbers of certain cell types, but not in the overall white blood cell (WBC) count. We found a significant effect of dose group on numbers of heterophils ($P = 0.010$) and monocytes ($P = 0.018$) (Fig. 2). Heterophils and monocytes increased

significantly in the high dose group by wk 11.

Immune function

All birds responded serologically to both BSA and EEEV. Peak BSA titers ranged from 1:40 to >1:1280; EEEV titers from 1:8 to 1:128. There were no significant differences between the control and low dose groups for peak or duration of titers, titers at wk 11, BSA titer, EEE titer, or the sum of BSA and EEE titers. The high dose group did not survive to finish the test. No difference was found between the groups when the PHA injection site swelling was measured. A biopsy taken of the test site was characterized by an increase in the number of layers of lymphocytes surrounding vessels in the low dose group when compared with the control or high dose groups (SDA, control vs. low dose, $P = 0.0063$; all three groups $P = 0.0588$). All but one of the high dose birds was included in the test.

Histology

When the low and control groups were compared, six histological observations, two in lung and four in hematopoietic tissues differed significantly and are listed in Table 1. All but two of the observations had dose related changes. Compared with controls, bone marrow cell density increased in the low dose group and decreased in the high dose group. A decrease in the lymphoid aggregates in the lungs of the low dose birds was not evident in the high dose group.

In the high dose group, 31 histology observations were significantly different (SDA, $P < 0.05$). Lesions in the nervous system tissue were exclusively seen in the high dose group. Sciatic nerve degeneration was characterized by loss of myelin, mild inflammation, decrease in diameter of the nerve, occasional axon swelling and a large proportion of the axons were missing or degenerate. Brachial nerves, on the other hand, had more severe and acute inflammation, and also had loss of myelin,

TABLE 1. Timing of statistically significant differences in various measurements relative to mercury concentrations in blood, growing feathers, and cumulative mercury consumed/weight (CumHg/Weight). Rows arranged in order of increasing CumHg/Weight.

Week	Dose group	Blood Hg (mg/kg)	Growing feather Hg (mg/kg)	CumHg/Weight (mg/kg)	Observation
5	Low	1.1	19	2.3	PCV decline (5–10 wk)
7	Low	2.4	33	3.6	—
9	Low	4.8	45	5.0	Dirty feathers (transient)
10	Low	—	—	5.3	Increased lymphocyte cuffing in delayed hypersensitivity test
11	Low	11.9	77	6.4	Decreased appetite and weight (Spalding et al., 2000)
14	Low	12.3	108	8.0	Decreased activity, sun tolerance and motivation to hunt (Bouton et al., 1999) Decreased bursal wall thickness Decreased lobule size in thymus Decreased lymphoid aggregates in lung Increased cellularity in bone marrow Decreased black pigment in lung Increased perivascular edema in lung
7	High	19.2	111	14.3	PCV decline (began at 5 wk)
10	High	—	—	44.4	Decreased lymphocyte cuffing in delayed hypersensitivity test Abnormal perching posture, increased righting time, altered wing and left foot responses, exaggerated palpebral reflex Decreased appetite and weight (Spalding et al., 2000)
10 to 12	High	74.4	770	45.0	Ataxia, unable to stand Severe neurologic changes Increase in monocytes and heterophils Severe pathology in many organs ^a

^a These changes are detailed in text of the results section.

severe vacuolation of nerve sheaths, and some axonal swelling indicating a more active process than in the sciatic nerve. Neuronal degeneration, as evidenced by neuron shrinkage and hyperchromasia, was observed most clearly in the pons with lesser involvement of neurons in the cerebellum and cerebrum. We could not detect any associated inflammatory changes or a loss of myelin in the brain using LFB stain, nor did we detect any endothelial changes. Degeneration of the spinal cord consisted of severe axon loss, axon swelling, and demyelination that were most severe in the dorsal funiculi and to a lesser extent in the lateral funiculi.

Severe changes also were noted in the immune system of the high dose group.

Atrophy of the bursa was noted both grossly and by using several measures; depletion of lymphocytes in the gland, the density of small lymphocytes in the pars lymphoepithelialis (cortex) was reduced, individual follicles were smaller, and the thickness of the wall and length of the gland were decreased. The thymus was markedly atrophic and barely visible grossly. When compared with the controls, it was significantly reduced in cross sectional area (length × width), individual lobules were reduced in size, and the number of stromal divisions per mm was increased. There was marked lymphoid depletion in the spleen and the cross sectional area (length × width) was decreased by 37%. Bone marrow had a decrease in cell den-

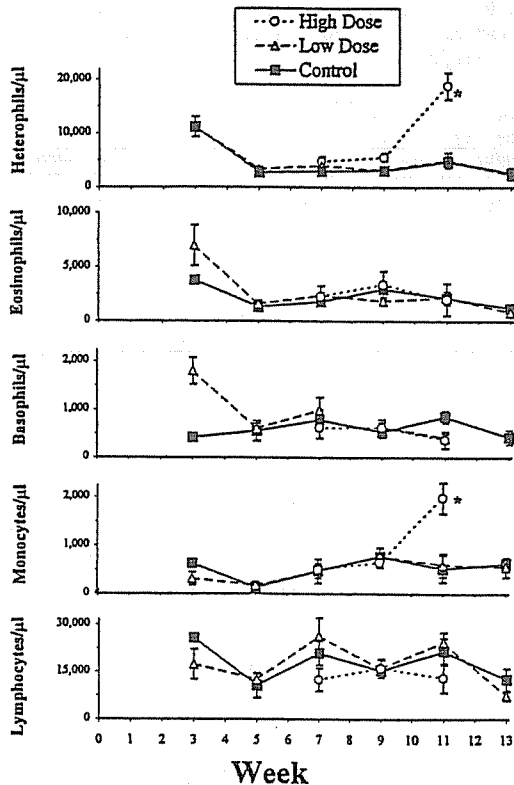


FIGURE 2. Biweekly differential white blood cell counts from great egret chicks dosed with methylmercury. High dose birds received the low dose until wk 5 and are combined with the low dose group during that period. Symbols with * differ significantly from the control group ($P < 0.01$).

sity, a decrease in the number of mitotic figures and an increase in the percentage of granulocytic cells.

Changes in the endocrine and exocrine systems of the high dose group also were noted. Adrenal medullary chromaffin cells had markedly vacuolated cytoplasm. There was disruption in the uniformity and vacuolation in the stratum granulosum of the ovary and the primary spermatocytes of the testes. Thyroid glands had a higher percentage of follicles that were distended with colloid and had flattened epithelium.

Other differences were observed in the lungs, kidneys, and liver of the high dose group. In the lungs there was no observable black pigment in parabronchial

macrophages, more perivascular edema and more mucoid distention of goblet cells within bronchiolar epithelium. In the kidney were an expansion of the uriniferous space within Bowman's capsule and nuclear vacuolation of the proximal tubular epithelia. Hepatocytes had significantly more small clear vacuoles in the cytoplasm. The livers had mixed periportal infiltrates that were more common and of greater extent than in the low and control dose groups. These infiltrates could not be distinguished from non-granulocytic extramedullary hematopoiesis.

No significant difference was found at the light microscope level between the groups for heart, heart Purkinje cells, ganglia and nerves in the intestinal tract, inflammatory infiltrates in the ventriculus, pancreas, liver fibrosis, inflammation in the liver that was not associated with portal areas, granulocytic extramedullary hematopoiesis in liver, adrenal cortical hyperplasia, density of germinal centers in spleen, pigment in gonads, follicle size in ovary, intestinal (ceca) lymphoid tissue, edema in a skin biopsy, and number of granulocytes infiltrating the skin biopsy site.

Neurological exam

Only one test distinguished the control from the low dose group. Feathers of both the low and high dose groups were significantly less clean at wk 9 than controls, and the high dose birds continued to be so at wk 10 (Table 1).

During wk 10, high dose birds responded differently from the control birds by having tremors while perching, a delayed righting time, exaggerated wing response to twisting the body, failing to place feet properly when toes were knuckled under, and having an exaggerated response to touching the eyelids (Table 1). In addition to these characteristics, the birds also showed head tremors, wider stance standing posture or were unable to stand, drooped wing posture, uneven gait, reduced ability to fly and land on a perch,

and exaggerated wing response to falling, immediately prior to euthanasia during wk 10–12.

DISCUSSION

Hematology and immunology

Anemia was the earliest change in dosed egrets detected in our study and has also been noted for mallards (*Anas platyrhynchos*) (Hoffman and Heinz 1998), and chickens (*Gallus gallus*) (Tejning 1967). While little to no quantitative information is available about the effects of this degree of anemia in birds, a 20% reduction in PCV is likely to have an effect on stamina. Anemia may have been responsible for the lethargy and decrease in active behaviors that was observed in this experiment (see Bouton et al., 1999), but it should be noted that when these observations were made, PCV was returning to normal. Evidence of red cell regeneration, polychromasia, occurred transiently after initiation of the higher dose, but we suspect that this regeneration was impaired later in the experiment based upon the findings of hypocellular bone marrow and continued PCV decline. A pattern of alternate peaking and declining in the PCV of all three groups for most of the experiment was probably a consequence of the larger volume of blood that was collected on alternate weeks. Generally, it is recommended that 1% of body weight of blood can be collected with no ill effects (Campbell, 1995). Further investigation into the effects of blood collection in young birds seems warranted. A gradual increase in PCV with age is normal in most birds and has been documented previously in ciconiforms (Montesinos et al., 1997). A decrease in plasma proteins can be caused by a wide range of factors including chronic hepatic and renal disease (Lewandowski et al., 1986).

The cause for the extreme heterophilia and monocytosis that occurred terminally in the high dose birds, could not be explained; there was no evidence of infectious agents. Wolfe and Norman (1998)

and Elbert and Anderson (1998) report changes in percentages of several white cell types in wild great blue heron (*Ardea herodias*) nestlings and grebes relative to mercury contamination, but without a total white cell count, increases or decreases in cell type could not be evaluated, nor could they be compared with our study. Increased numbers of peripheral blood heterophils and decreased numbers of lymphocytes were noted in young chickens dosed with inorganic mercury (Bridger and Thaxton, 1983). In vitro studies of mercury toxicity have shown concentrations of methylmercury chloride in the range of 10^{-7} to 10^{-6} M (0.025 to 0.25 mg/kg) to affect cell viability (LD50) and lymphocyte function in the mouse and human, including reduced mitogenicity responses and inhibited mixed lymphocyte responses (Nakatsuru et al., 1985; Shenker et al., 1992a, b). Preliminary data from an in vitro study using nestling great egret lymphocytes exposed to methylmercury chloride indicated acute loss of cell viability of both T and B lymphocytes by 1 hr at 25 mg/kg and by 12 hr at 2.5 mg/kg (L. J. Richey, unpubl. data). In vivo no significant decline in peripheral lymphocytes even at blood concentrations as high as 60 mg/kg was observed in our study, but response to a mitogen (PHA) was decreased in the high dose group.

One of the most curious changes noted was a dose related negative association between methylmercury and black material in parabronchiolar macrophages of the lungs in both dosed groups. This material was most likely carbon inhaled due to the presence of a nearby highway, and taken up by macrophages. Since all birds were exposed similarly, a likely explanation is that phagocytosis by macrophages was inhibited in dosed animals. Mercury chloride has been shown to inhibit erythrophagocytosis by peritoneal macrophages in some rat strains in vitro (Contrino et al., 1992), and monocytes may be more sensitive to mercury than lymphocytes (Steffensen et al., 1994).

The effects of methylmercury on the humoral responses of the low dose group were confounded by several factors, and are inconclusive. The high dose group did not complete the test. Extreme individual variability in responses to the antigens in this study was probably due to individual differences in maturity of the immune system. Only inorganic mercury has been used to test the immune function of birds, domestic chickens being the most commonly studied. Oral dosing of mercuric chloride in domestic broiler chicks resulted in decreased primary and secondary hemagglutinin responses to sheep red blood cells (Thaxton and Parkhurst, 1973; Bridger and Thaxton, 1983), suppressed primary agglutinin responses to *Brucella abortus* (Bridger and Thaxton, 1983), and decreased agglutinin responses to *Salmonella* (Thaxton and Parkhurst, 1973).

Ilback (1991) noted a decrease in thymus but not spleen weight in methylmercury dosed mice. The most dramatic immune system alterations in the egrets were in the gross and histologic appearance of the bursa and thymus. In chickens oral dosing with inorganic mercury resulted in decreased weights of thymus, spleen, and bursa (Thaxton, 1973). In humans with Minamata disease, hypoplasia and aplasia of bone marrow was observed (Takeuchi, 1972).

Nervous system

For the low dose group we found no neurohistologic changes that would explain the subtle behavioral changes noted by Bouton et al. (1999) between low and control groups, and our only other evidence of neurological manifestations of mercury dosing was of dingy feathers. We did not see, nor can we address developmental neuropathologic changes reviewed by Burbacher et al. (1990) for mammals, since all our groups received similar uncontrolled background levels during embryonic development and were not dosed during the first wk of captivity.

Ataxia, progressing to paralysis has been

described in non-fish-eating birds dosed with methylmercury (Borg et al., 1970; Fimreite and Karstad, 1971; Pass et al., 1975; Heinz and Hoffman, 1998). Surprisingly, postural, ambulatory, and motivational deficits appeared to precede loss of foraging skills in low-dosed birds (Bouton et al., 1999). Ataxic birds in our high dose group were still able to capture live fish. The most severe lesions in high dosed birds were in peripheral nerves and spinal cord, followed by midbrain, cerebellum and cerebrum. These changes occurred at a mean of 35 mg/kg mercury in the brain which is generally higher than reported in other animals and humans (Heinz, 1996). The lesions in both peripheral and central nervous tissue were similar to those described in goshawks (*Accipiter gentilis*) with about 40 mg/kg mercury in brain by Borg et al. (1970), except that we did not see the interstitial fibrosis in peripheral nerves that they described. We did not observe the atrophic changes in the granular layer of the cerebellum reported in mammals (Nagashima, 1997 in the rat; Koller et al., 1997 in the rabbit; Gruber et al., 1978 in the cat). We also did not observe fibrinoid degeneration of vessel walls in the brain that was reported by Pass et al. (1975), even though blood mercury concentrations in our study exceeded theirs. Heinz and Locke (1976) reported demyelination, neuron shrinkage, necrosis, and cerebellar meningeal hemorrhage in offspring of mallards fed methylmercury. Mercury measured in the brains of the ducklings that died within a few days of hatching ranged from 4 to 9 mg/kg, adding support to the hypothesis that embryos may be more sensitive than adult or juvenile birds.

In peripheral nerves, there was a marked difference between the lesions in brachial and sciatic nerves. In the sciatic nerves very little inflammation was observed and the lesions consisted of neuronal loss, atrophy and demyelination. The brachial nerves had marked Wallerian degeneration indicating a more acute pro-

cess. This may explain the loss of hind limb function first, as has been reported also in humans (Takeuchi, 1972) and guinea pigs (Yamini and Sleight, 1973). Although ataxia is frequently reported in birds with methylmercury toxicosis, the effects on flight are noted rarely.

Histology of other organs

Degenerative changes, characterized at the light microscopic level by vacuolar change, have been reported also in methylmercury chloride dosed ducks in Sertoli cells and primary spermatocytes (McNeil and Bhatnagar, 1985), and in interstitium and Leydig cells (McNeil et al., 1985). Methylmercury influences thyroid function in fish (Bleau et al., 1997), but we could find no reports for birds. Backstrom (1969) using autoradiographic techniques demonstrated greater uptake of methylmercury by thyroid and adrenal medullary cells when compared to intrarenal cells.

In a summary of the effects of methylmercury in birds, Heinz (1996) suggested that 10–60 mg/kg mercury in kidney may be harmful. In a study of goshawks (Borg et al., 1970), and our study, only subtle histologic changes in the kidneys with >100 mg/kg indicates that some species might be more refractory to mercury damage than other species. In dosed adult ducks, Pass et al. (1975) noted degeneration and necrosis of tubular epithelial cells at all levels of the nephron when kidney mercury concentrations were at 5.7 mg/kg, well below the concentration at which we observed changes.

Vacuolar degeneration of hepatocytes was noted in humans with Minamata disease (Takeuchi, 1972), and Bhatnagar et al. (1982) at the ultrastructural level in pekin ducks (*Anas platyrhynchos*) fed methylmercury to about 90 mg/kg in liver.

Some, but not all, of the lesions described in the high dose great egrets were similar to those in ducks fed seleno-DL-methionine (Albers et al., 1996; Green and Albers, 1997). Liver selenium concentrations in the ducks were similar to birds in

our study (Spalding et al., 2000). We could not rule out the possibility that selenosis caused or contributed to some of the lesions we observed. It is also possible that the selenium that was preferentially absorbed in the high dose birds was protective, decreasing the severity of the lesions. Administering methylmercury along with a selenium deficient diet would test this hypothesis.

Comparison with wild birds

Our attempts to compare effects observed at specific mercury concentrations in the lab with studies of wild birds were complicated by inconsistencies in ages, tissues tested, species, dose, food consumption rates, variability in dose, dose duration, and responses measured. We attempted to address this problem by standardizing exposure using the actual (in the case of captive birds) or estimated (using equations in Table 2 from Spalding et al., 2000) cumulative methylmercury consumed per body weight (CumHg/Weight).

The lowest observed adverse effect level (LOAEL) that we were able to detect in our study was a decline in PCV when nestlings had ingested a total of 2 mg/kg methylmercury. A trend toward decreased PCV was not observed until an estimated 5 mg/kg had been consumed in wild dosed nestlings (Sepulveda et al., 1999b). We suspect that uncontrolled factors in their study, such as younger age (4 wk at end of experiment), ambient mercury exposure in controls (0.41 mg/kg in diet), and variability in PCV due to sex, hydration status, and infectious disease, would decrease the probability of detecting a sublethal change.

A measurable effect upon immune system function, a delayed-hypersensitivity skin test, was documented in our captive study when 6 mg/kg had been consumed. Observations from field studies suggest that in wild birds functional changes in the immune system may occur at lower exposure rates. Spalding et al. (1994) found a threshold for chronic disease in juvenile

TABLE 2. Health observations in wild nestling and juvenile ardeids associated with methylmercury exposure. Observations are ordered based on calculated cumulative methylmercury per kg body weight (CumHg/Weight).

Total mercury mg/kg wet weight	Tissue	Calculated CumHg/ Weight mg/kg ^a	Wild egrets and herons ^b	Source ^c
3.2	Feather	0.4	Average for live nestlings (GBH) (Rodman Slough, Clear Lake, California, USA)	A
16	Growing feather	2	Average for live nestlings	B
6.6	Liver	3	Average of dead nestlings (GBH)	C
>6	Liver	>3	Threshold for chronic disease (GWH)	D
52	Growing feather	5	Decreased appetite and trend to PCV and lymphocyte decline in wild dosed nestlings	E,F
59	Growing feather	6	Highest in living alert nestlings	G
18	Liver	8	Moribund nestling	C
18	Blood	21	Unable to fly juvenile (GBH)	C
75	Liver	28	Unable to fly juvenile (GBH)	C

^a Growing feather values were used when available (Feather concentration = $8.0599x^{1.1456}$), otherwise, blood (Blood concentration = $1.0188x^{0.9494}$), liver (Liver concentration = $1.5798x^{1.1602}$), or brain (Brain concentration = $0.9754x^{1.0136}$) concentrations were converted ($x = \text{CumHg/Weight in mg/kg}$) (Spalding et al., 2000).

^b All are great egret nestlings/fledglings from the Everglades (Florida, USA) except where indicated. GWH = great white heron, GBH = great blue heron.

^c Source: A = Wolfe and Norman, 1998; B = Sepulveda et al., 1999a; C = Sundlof et al., 1994; D = Spalding et al., 1994; E = Williams, 1997; F = Sepulveda, 1999b; G = Spalding, unpubl. data.

great white herons at >3 mg/kg and Sepulveda et al. (1999b) noted a trend toward decline in lymphocyte numbers at 5 mg/kg.

We also compared our results with field observations of compromised individual ardeids (Table 2). The highest recorded concentration (in liver) of mercury in a great egret nestling from the Everglades was the equivalent of 8 mg/kg CumHg/Weight. This nestling was found moribund and severely emaciated (Sundlof et al., 1994). Histologic findings included perivascular edema in the lung, hepatic atrophy, moderate lymphoid depletion of spleen, and no significant lesions in kidney or brain. Two juvenile great blue herons found in the Everglades that could not fly were estimated to have consumed 21 and 28 mg/kg. In these cases also no other cause for debilitation and emaciation was found at death, but histologic evaluation was impossible because tissues were frozen. The captive great egrets, on the other hand, did not become severely ataxic and

unable to stand until 49 mg/kg had been consumed. Tissue concentrations on this order have never been reported in wild ciconiiformes. This information suggests that severe debilitating effects may occur in the wild at lower thresholds of mercury consumption than in captivity.

To summarize, thresholds for sublethal endpoints measured in captive birds were lower than those measured in wild birds, probably due to the increased detectability inherent in controlled laboratory experiments. In the field, large sample sizes and rigorous methods would be necessary to match the detectability of laboratory experiments. Conversely, at the higher end of the exposure continuum, thresholds for more life-threatening endpoints appeared to be lower in wild birds possibly due to the synergistic effects of various stressors from which captive birds were protected. Thus LOELs from captive experiments are likely to be more accurate when applied to field situations than vice versa. In conclusion, our results indicate that many

great egret nestlings in the Everglades are likely to be experiencing the chronic, sublethal effects of methylmercury poisoning. Our ability to detect effects of methylmercury at doses lower than the LOAEL we report was limited by the nature of our study design, and it is possible that effects occur below this level.

ACKNOWLEDGMENTS

This study was funded by the Florida Department of Environmental Protection and the U.S. Fish and Wildlife Service. Discussions and support by T. Atkeson were integral in the design of the project. We thank M. Avery and his staff for providing housing for birds. F. Burnett and G. Jones gave statistical assistance. E. Dusenbery, M. Sepulveda, T. Fitzpatrick, J. Arreca, K. Roca, D. Hoffman, C. Allen, D. Forrester, D. Axelrad, R. Koppleman, S. Schaack, R. Bireline, and T. Cames all assisted with various parts of this study. The serologic work at the University of Notre Dame, Laboratory for Arbovirus Research and Surveillance was supported in part by NIH grant AI-02753 (P. Grimstad), NIH training grant AI-07030 (K. Rai) and the Indiana State Department of Health. This is Journal Series R-07212 of the Florida Agricultural Experiment Station.

LITERATURE CITED

- ALBERS, P. H., D. E. GREEN, AND C. J. SANDERSON. 1996. Diagnostic criteria for selenium toxicosis in aquatic birds: dietary exposure, tissue concentrations, and macroscopic effects. *Journal of Wildlife Diseases* 32: 468-485.
- BACKSTROM, J. 1969. Distribution studies of mercuric pesticides in quail and some freshwater fishes. *Acta Pharmacologica et Toxicologica* 27 (Supplement 3): 1-103.
- BARR, J. F. 1986. Population dynamics of the common loon (*Gavia immer*) associated with mercury-contaminated waters in northwestern Ontario. Canadian Wildlife Service, Guelph, Ontario, Canada, Occasional Paper No. 56, 23 pp.
- BHATNAGAR, M. K., O. E. VRABLIC, AND S. YAMASHIRO. 1982. Ultrastructural alterations of the liver of Pekin ducks fed methyl mercury-containing diets. *Journal of Toxicology and Environmental Health* 10: 981-1003.
- BLEAU, H., C. DANIEL, G. CHEVALIER, H. VAN TRA, AND A. MONTELA. 1997. Effects of acute exposure to mercury chloride and methylmercury on plasma cortisol, TT, T4, glucose and liver glycogen in rainbow trout (*Oncorhynchus mykiss*). *Reviews in Environmental Health* 12: 107-116.
- BORG, K., K. ERNE, E. HANKO, AND H. WANNTORP. 1970. Experimental secondary methyl mercury poisoning in the goshawk (*Accipiter g. gentilis* L.). *Environmental Pollution* 1: 91-104.
- BOUTON, S. N., P. C. FREDERICK, M. G. SPALDING, AND H. MCGILL. 1999. Effects of chronic, low concentrations of dietary methylmercury on the behavior of juvenile great egrets. *Environmental Toxicology and Chemistry* 18: 1934-1939.
- BRIDGER, M. A., AND J. P. THAXTON. 1983. Humoral immunity in the chicken as affected by mercury. *Archives of Environmental Contamination and Toxicology* 12: 45-49.
- BURBACHER, T. M., P. M. RODIER, AND B. WEISS. 1990. Methylmercury developmental neurotoxicity: a comparison of effects in humans and animals. *Neurotoxicology and Teratology* 12: 191-202.
- CAMPBELL, T. W. 1995. Avian hematology and cytology. Iowa State University Press, Ames Iowa, 104 pp.
- CHANG, L. W. 1977. Neurotoxic effects of mercury—A review. *Environmental Research* 14: 329-373.
- CLECKNER, L. B., P. J. GARRISON, J. P. HURLEY, M. L. OLSON, AND D. P. KRABBENHOFT. 1998. Trophic transfer of methyl mercury in the northern Florida Everglades. *Biogeochemistry* 40: 347-361.
- CONTRINO, J., L. L. KOSUDA, P. MARUCHA, D. L. KREUTZER, AND P. E. BIGAZZI. 1992. The in vitro effects of mercury on peritoneal leukocytes (PMN and macrophages) from inbred brown Norway and Lewis rats. *International Journal of Immunopharmacology* 14: 1051-1059.
- ELBERT, R. A., AND D. W. ANDERSON. 1998. Mercury levels, reproduction, and hematology in western grebes from three California lakes, U.S.A. *Environmental Toxicology and Chemistry* 17: 210-213.
- FABER, R. A., AND J. J. HICKEY. 1973. Eggshell thinning, chlorinated hydrocarbons, and mercury in inland aquatic bird eggs, 1969 and 1970. *Pesticide Monitoring Journal* 7: 27-36.
- FACEMIRE, C., T. AUGSBURGER, D. BATEMAN, M. BRIM, P. CONZELMANN, S. DELCHAMPS, E. DOUGLAS, L. INMON, K. LOONEY, F. LOPEZ, G. MASSON, D. MORRISON, N. MORSE, AND A. ROBISON. 1995. Impacts of mercury contamination in the southeastern United States. *Water, Air, and Soil Pollution* 80: 923-926.
- FIMREITE, N. 1974. Mercury contamination of aquatic birds in northwestern Ontario. *The Journal of Wildlife Management* 38: 120-131.
- , AND L. KARSTAD. 1971. Effects of dietary methyl mercury on red-tailed hawks. *The Journal of Wildlife Management* 35: 293-330.
- FREDERICK, P. C., M. G. SPALDING, M. S. SEPULVEDA, G. E. WILLIAMS, L. NICO, AND R. ROBINS. 1999. Exposure of great egret (*Ardea albus*) nestlings to mercury through diet in the Everglades

- ecosystem. *Environmental Contamination and Toxicology* 18: 1940-1947.
- GREEN, D. E., AND P. H. ALBERS. 1997. Diagnosis criteria for selenium toxicosis in aquatic birds: Histological lesions. *Journal of Wildlife Diseases* 33: 385-404.
- GRUBER, T. A., P. COSTIGAN, G. T. WILKINSON, AND A. A. SEAWRIGHT. 1978. Chronic methylmercurialism in the cat. *Australian Veterinary Journal* 54: 155-160.
- HEINZ, G. H. 1975. Effects of methylmercury on approach and avoidance behavior of mallard ducklings. *Bulletin of Environmental Contamination and Toxicology* 13: 554-564.
- . 1976. Methylmercury: second generation reproductive and behavioral effects on mallard ducks. *The Journal of Wildlife Management* 40: 710-715.
- . 1979. Methylmercury: Reproductive and behavioral effects on three generations of mallard ducks. *The Journal of Wildlife Management* 43: 394-401.
- . 1996. Mercury poisoning in wildlife. In *Non-infectious diseases of wildlife*, A. Fairbrother, L. N. Locke, and G. L. Hoff (eds.). Iowa State University Press, Ames, Iowa, pp. 118-127.
- , AND D. J. HOFFMAN. 1998. Methylmercury chloride and selenomethionine interactions on health and reproduction in mallards. *Environmental Toxicology and Chemistry* 17: 139-145.
- , AND L. N. LOCKE. 1976. Brain lesions in mallard ducklings from parents fed methylmercury. *Avian Diseases* 20: 9-17.
- HOFFMAN, D. J., AND G. H. HEINZ. 1998. Effects of mercury and selenium on glutathione metabolism and oxidative stress in mallard ducks. *Environmental Toxicology and Chemistry* 17: 161-166.
- HUGHES, J. A., E. ROSENTHAL, AND S. B. SPARBER. 1976. Time dependent effects produced in chicks after prenatal injection of methylmercury. *Pharmacology Biochemistry and Behavior* 4: 507-513.
- ILBACK, N. G. 1991. Effects of methyl mercury exposure on spleen and blood natural killer (NK) cell activity in the mouse. *Toxicology* 67: 117-124.
- , L. WESSLEN, J. FOHLMAN, AND G. FRIMAN. 1996. Effects of methyl mercury on cytokines, inflammation and virus clearance in a common infection (coxsackie B3 myocarditis). *Toxicological Letters* 89: 19-28.
- JURCZYK, N. U. 1993. An ecological risk assessment of the impact of mercury contamination in the Florida Everglades. M.S. Thesis, University of Florida, Gainesville, Florida, 119 pp.
- KOLLER, L. D., J. H. EXON, AND B. ARBOGAST. 1977. Methylmercury: Effect on serum enzymes and humoral antibody. *Journal of Toxicology and Environmental Health* 2: 1115-1123.
- LEWANDOWSKI, A. H., T. W. CAMPBELL, AND G. J. HARRISON. 1986. Clinical chemistries. In *Clinical avian medicine and surgery*, G. J. Harrison and L. R. Harrison (eds.). W. B. Saunders Company, Philadelphia, Pennsylvania, pp. 192-200.
- LILLIE, R. D. 1976. *Histopathologic techniques and practical histochemistry*. 4th Edition. McGraw-Hill, New York, New York, 942 pp.
- LINDSEY, H. S., C. H. CALISHER, AND J. H. MATHEWS. 1976. Serum dilution neutralization test for California group virus identification and serology. *Journal of Clinical Microbiology* 4: 503-510.
- LUNG, N. P., J. P. THOMPSON, G. V. KOLLIAS, J. H. OLSEN, J. A. ZDZIARSKI, AND P. A. KLEIN. 1996. Maternal immunoglobulin G antibody transfer and development of immunoglobulin G antibody responses in blue and gold macaw chicks (*Ararauna*). *American Journal of Veterinary Research* 57: 1162-1167.
- MCNEIL, S. I., AND M. K. BHATNAGAR. 1985. Ultrastructure of the testis of pekin ducks fed methyl mercury chloride: Seminiferous epithelium. *American Journal of Veterinary Research* 46: 2019-2025.
- , ———, AND A. SINGH. 1985. Testes interstitium in ducks fed methyl mercury. *Anatomic Record* 211: 362.
- MEYER, M. W., D. C. EVERS, T. DAULTON, AND W. E. BRASELTON. 1995. Common loons (*Gavia immer*) nesting on low pH lakes in northern Wisconsin have elevated blood mercury content. *Water, Air, and Soil Pollution* 80: 1-4.
- , ———, J. J. HARTIGAN, AND P. S. RASMUSSEN. 1998. Patterns of common loon (*Gavia immer*) mercury exposure, reproduction, and survival in Wisconsin, U.S.A. *Environmental Toxicology and Chemistry* 17: 184-190.
- MONTESINOS, A., A. SIANZ, M. V. PABLOS, F. MAZ-ZUCHELLI, AND M. A. TESOURO. 1997. Hematological and plasma biochemical reference intervals in young white storks. *Journal of Wildlife Diseases* 33: 405-412.
- NAGASHIMA, K. 1997. A review of experimental methylmercury toxicity in rats: Neuropathology and evidence for apoptosis. *Toxicologic Pathology* 25: 624-631.
- NAKATSURU, S., J. OOHASHI, H. NOZAKI, S. NAKADA, AND N. IMURA. 1985. Effect of mercurials on lymphocyte functions in vitro. *Toxicology* 36: 297-305.
- NOCERA, J. J., AND P. D. TAYLOR. 1998. In situ behavioral response of common loons associated with elevated mercury (Hg) exposure. *Conservation Ecology* [online] 2(2): 10 (Available from the Internet. URL: <http://www.consecol.org/vol2/iss2/art10>).
- PANTUWATANA, S., W. H. THOMPSON, D. M. WATTS, AND R. P. HANSON. 1972. Experimental infection of chipmunks and squirrels with La Crosse and